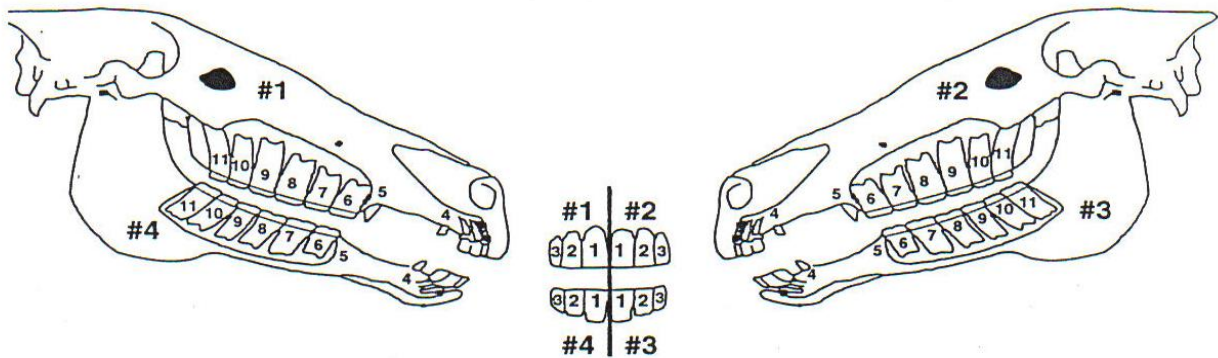


# January 2017: Getting long in the tooth

This month we're exploring equine dentistry from a functional perspective to understand how regular dental care contributes to a happier mouth (and horse!).

## A few key points to remember about equine teeth:

- If we split the equine head into 4 quadrants, each quadrant contains 3 incisor teeth, 1 canine tooth (generally in male horses only), 4 premolars (1<sup>st</sup> premolar is the wolf tooth), and 3 molars. The last 3 premolars and the 3 molar teeth are anatomically and functionally similar. Together all 6 are classified as cheek teeth because they act as one functional grinding unit.

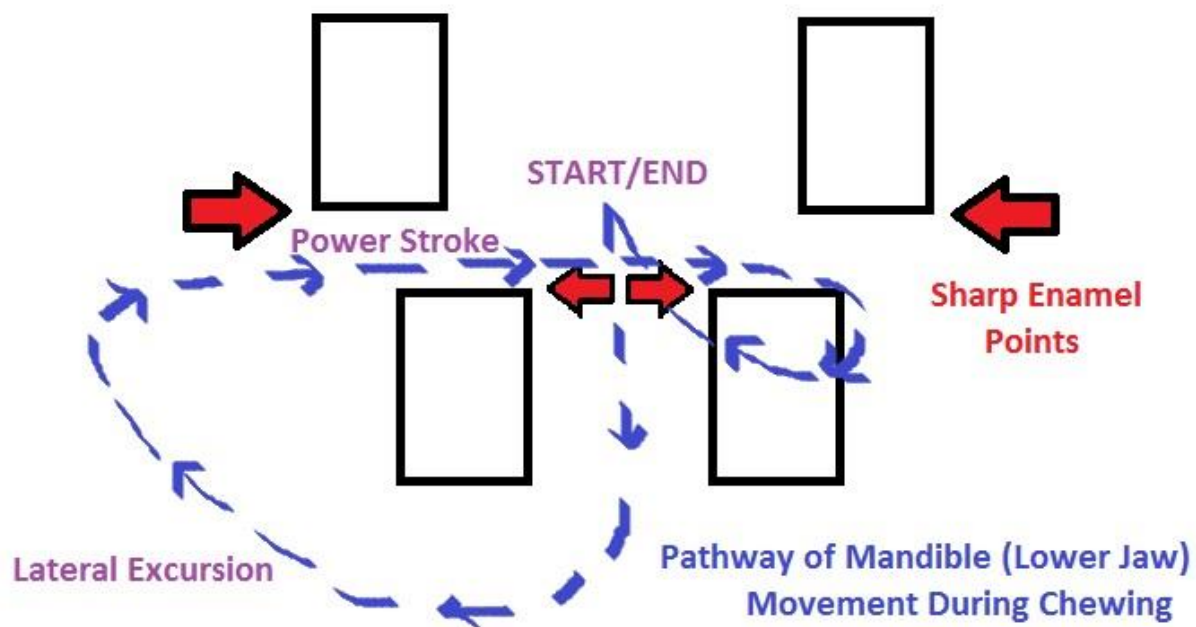


*Dental diagram showing the triadan system for numbering teeth that veterinarians use for record keeping. The head is split into 4 quadrants and individual teeth are numbered from the innermost incisor to the last molar. For example, the second premolar on the upper right arcade is numbered 206.*

- Equine teeth have evolved to grind fibrous feed. The insides of the cheek teeth contain ribbons of hard enamel, the same tissue that covers the outside of human teeth.
- Adult horses continue to erupt reserve crown into their 20s. Older horses develop a smooth mouth once their enamel has been worn away, and are unable to grind fibrous hays effectively. Diets in older horses should be modified to include softer senior concentrate feeds.
- Unlike in people where periodontal (gum) disease is caused by build up of tartar, periodontal disease in horses is generally associated with malocclusions i.e. abnormal positioning of the cheek teeth. Malocclusions can be caused by abnormal eruption of permanent teeth or abnormal tooth wear caused by asymmetrical skeletal anatomy or avoidance of chewing with painful, diseased teeth.

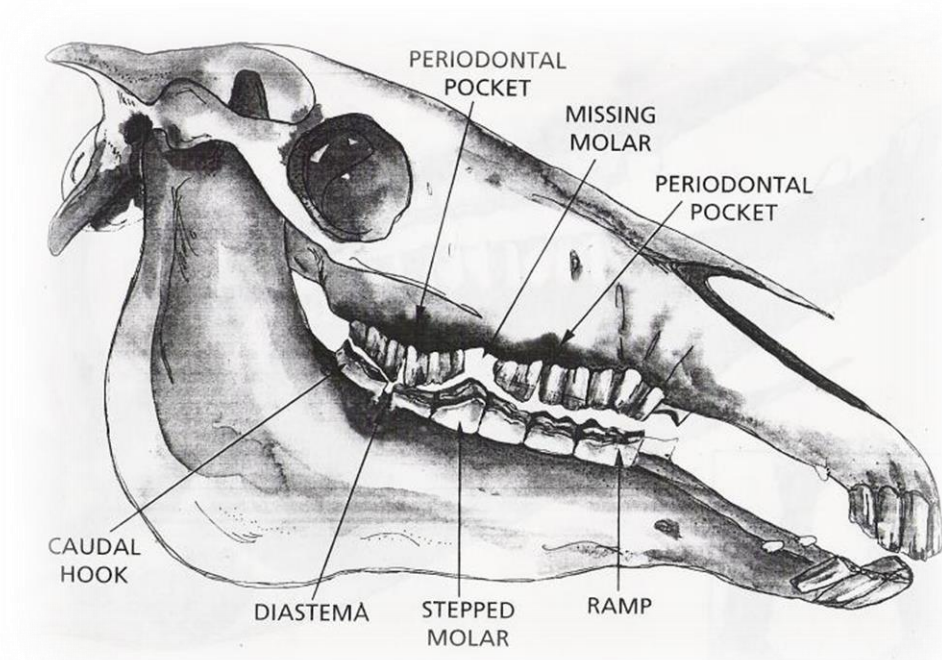
## How does normal anatomy and chewing motion affect tooth growth?

A big part of what determines how a horse chews is the anatomy of their skull and dental arcades. In the horse, the maxilla (upper jaw) is wider than the mandible (lower jaw). At rest the incisors meet but the cheek teeth are not in contact, leaving an empty space between the upper and lower arcades. As the chewing cycle starts, the mandible moves down and out to the side before moving upwards to contact the maxilla. Only one side is able to chew at a time meaning that mandible on one side comes in contact with the maxilla on the same side. The power stroke occurs when the arcades come into full occlusion; this is when feed is actively ground into smaller, more digestible portions. The mandible moves all the way across that side of the maxilla, and then resets before starting the chewing cycle over again. Because the mandible and maxilla are off set and only come into occlusion during chewing, sharp enamel points tend to form on the outer cheek surface of the maxillary teeth and the inner tongue surface of the mandibular teeth. Sharp enamel points should be floated regularly to prevent ulceration of soft tissue and pain during chewing and resistance to the bit.



### What types of abnormal tooth growth patterns can occur?

Anything that interferes with the horse's ability to perform a chewing cycle is a malocclusion. Common malocclusions include hooks, ramps, steps, and waves. Hooks can cause associated trauma to the gums, cheeks, and tongue. Due to the horse's anatomy, hooks tend to form on the upper first cheek teeth (106/206) and lower last cheek teeth (311/411). Ramps, steps, and waves develop when healthy teeth are not worn down during the chewing cycle as they should be. Usually the teeth opposing the overgrown teeth are diseased or misplaced anatomically. A degree of ramping occurs naturally in the lower back teeth due to the normal curve of the mandible and should not be excessively floated. Steps, where one tooth grows excessively long, are usually an indication that the opposing tooth is missing, diseased, or has run out of reserve crown. Waves, which occur along an entire row of cheek teeth, can become permanent in older horses as the jaw bones will remodel to match the shape of the wave. Waves need to be managed in older horses to keep their chewing cycle functional.



### What are the consequences of abnormal tooth growth patterns?

Malocclusions can make it impossible for the horse to perform a full chewing cycle, which if left uncorrected can exacerbate overgrowths over time. The chewing cycle can be evaluated by moving the mandible back and forth with the incisors in contact to see how far the mandible can be slid in either direction before the cheek teeth come in to occlusion and the incisors separate. This test can give an indication of obstructions to normal movement.

Focal overgrowths in the arcade can cause separation between teeth in the opposing arcade, forming diastema (gaps) between teeth. Feed gets packed into diastema which can cause periodontal disease and eventually tooth root infections.

**How can abnormal tooth growth patterns be prevented or corrected?**

Regular veterinary dental examinations and targeted floating to correct focal overgrowths are key to preventing long term dental problems like periodontal disease and tooth root infections. In horses with advanced dental disease, more frequent floating can make gradual corrections that will make the horse more comfortable and help them chew effectively. The goal of a dental float is to optimize the function of a mouth, not to make the dental arcades fit the mold of what we consider to be perfect. Each horse is an individual with different skull and dental anatomy, and if each mouth is subjected to the same dental float approach, there is a risk of causing pulp exposure, dental pain, and preventing the horse from chewing normally. That's why we highly recommend yearly dental examinations and corrective floating performed by an experienced veterinarian.

**February is dentistry month at Delaney Veterinary Services. We will be offering discounts on dental exams and floats. Please contact us for further information!**

By Dr. Hannah Smith, BVM&S

Associate Veterinarian